

# Case presentation

Prof. Peter Tenke

Jahn Ferenc South-Pest Teaching Hospital,  
Budapest



## B.K. 17-year-old man

- Symptoms: tiredness, some tenderness below the 12th rib on the right side.

- Went to see his GP

(again a young man, who does not want to go to school, but let me see...)

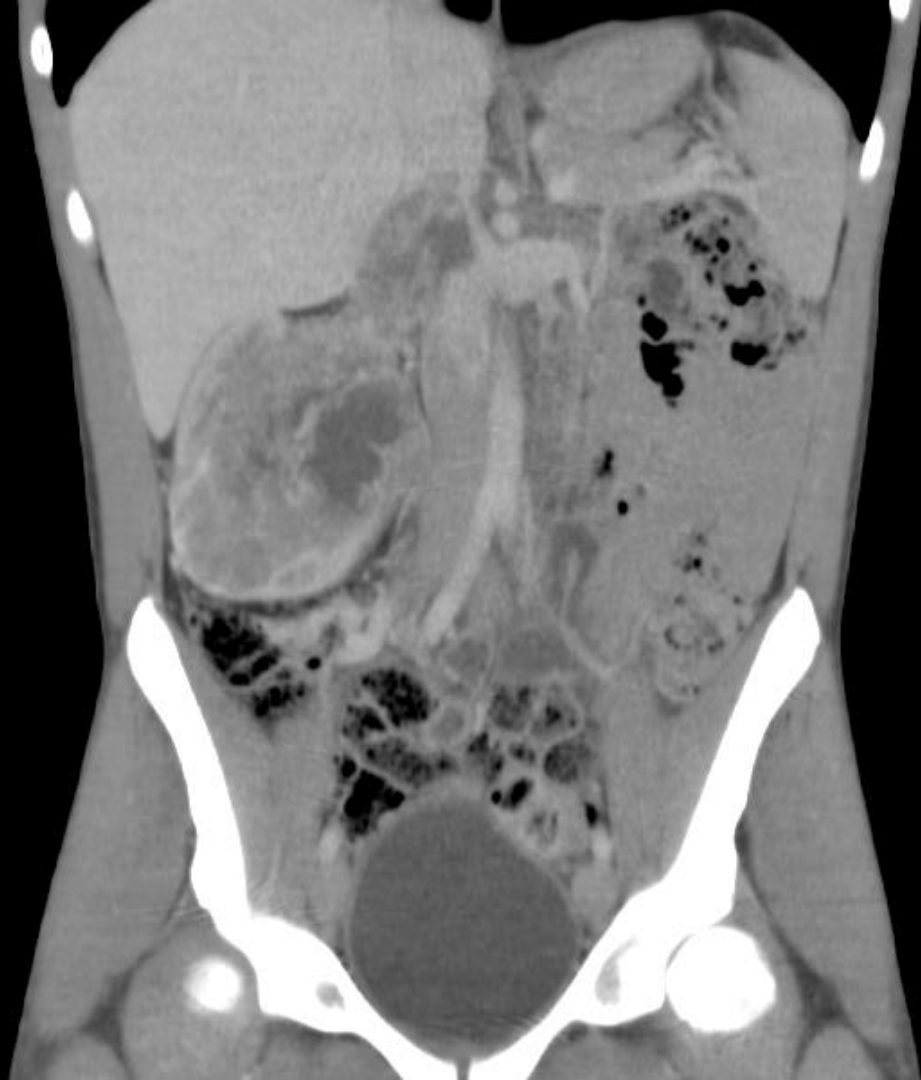

- GP ordered: laboratory investigations and US
- Lab: LDH is 2x than normal (958U/l), without any other significant differences
- Abdominal US: large tumor in the right kidney, invades the inferior vena cava (2012 May)



- Chest and abdominal CT scan (14th May):
- Large tumor mass in the right kidney (112x114x100mm), dislocates the intestines and seems to infiltrate the abdominal wall. The tumor invades the right renal vein and the inferior vena cava. The tumor thrombus is 49x35mm, just above the left renal vein and it is just about to reach the hepatic veins level.





## Other bad news:

- Metastasis suspect small terimes in the lungs (3-8mm)
- Lymphadenomegaly next to the aorta (5-7mm)



# Arising problems

- Young age - not clear renal cell carcinoma
  - ✓ late onset Wilms tumor
  - ✓ some kind of rare type of tumor (For sarcomas the chemotherapy can be very effective)
- Operations risk is very high- size of the tumor and trombus



# What would be the next step?

1. Operation with thoracic surgeon?
2. Metastatic disease: debulking operation+adjuvant chemotherapy?
3. Biopsy- therapy according to histology results?
4. Best supportive care?





# Renal biopsy-Accurate and Safe

- Volpe et al J Urol 2007. Literature review. **Needle biopsy provides accurate diagnosis in more than 90% of renal masses.**
- Leveridge et al Eur Urol 2011. Biopsy diagnostic in 81%.
- Mally et al Can J Urol 2012. Only 10-15% of small renal mass biopsies were indeterminate.
- Menogue et al BJU Intl 2012. **Biopsy was 100% accurate distinguishing benign from malignant lesions.**
- Shannon et al J Urol 2012. Of patients undergoing surgery, biopsy was 100% accurate distinguishing malignant from benign lesions. Complications in 2 pts (0,9%).



- Fine needle aspiration biopsy: 2012 May
- Diagnosis: malignant kidney tumor
- Histology result: the malignant tumor PNET (primitiv neuroectodermal tumor) or synovial sarcoma.



- Ewing-VIDE protocol 4 cycles of chemotherapy combination

- ✓ 3days x 50mg Epirubicin
- ✓ 3days x 3000mg Holoxan (ifosfamide)
- ✓ 4days x 4000mg Uromitexan (mesna)
- ✓ 1day x 2mg Vincristine
- ✓ 3days x 100mg Etoposide



- After two cycles of chemotherapy control CT scan was done ( 2012 July):
- The tumor in the right kidney did not grow, the tumor thrombus in the veins hasn't grown
- In the lungs: no abnormality is detected

*Summary:* there is no change in the abdomen, but there are no more suspect lesions in the lungs.



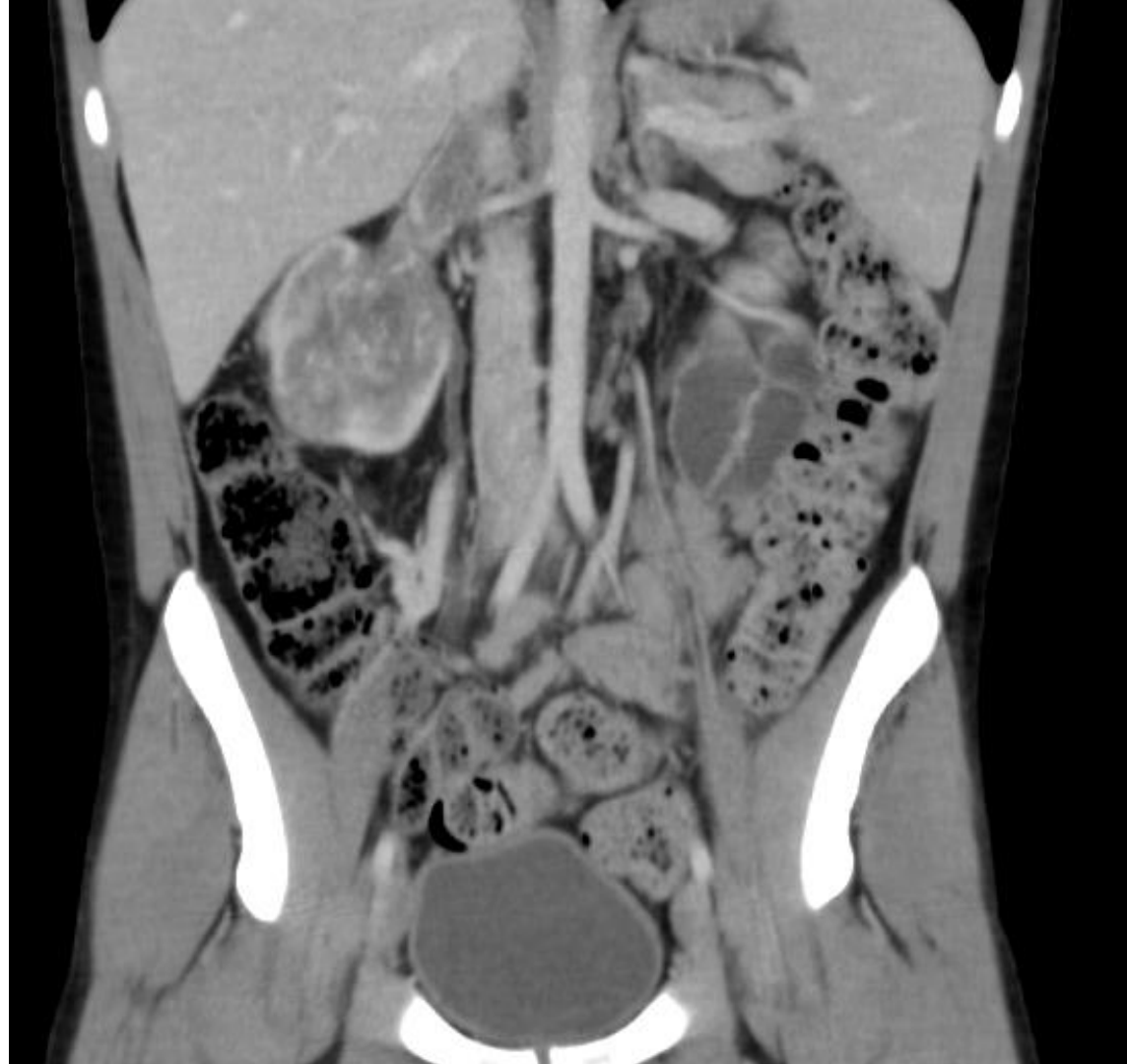# What would be the next step?

1. Operation: radical nephrectomy with thoracic surgeon?
2. Continue chemotherapy?
3. To change chemotherapy protocol?
4. Best supportive care?



- After 4th cycle of chemotherapy control CT scan was done ( 2012 September)
- The tumor in the right kidney shows regression :
- The tumor size is smaller (65x45x75mm), the intestine dislocation has disappeared.





- Nephrectomy with lymphadenectomy was done.

(2012 October )

- Final histology: Kidney Ewing sarcoma

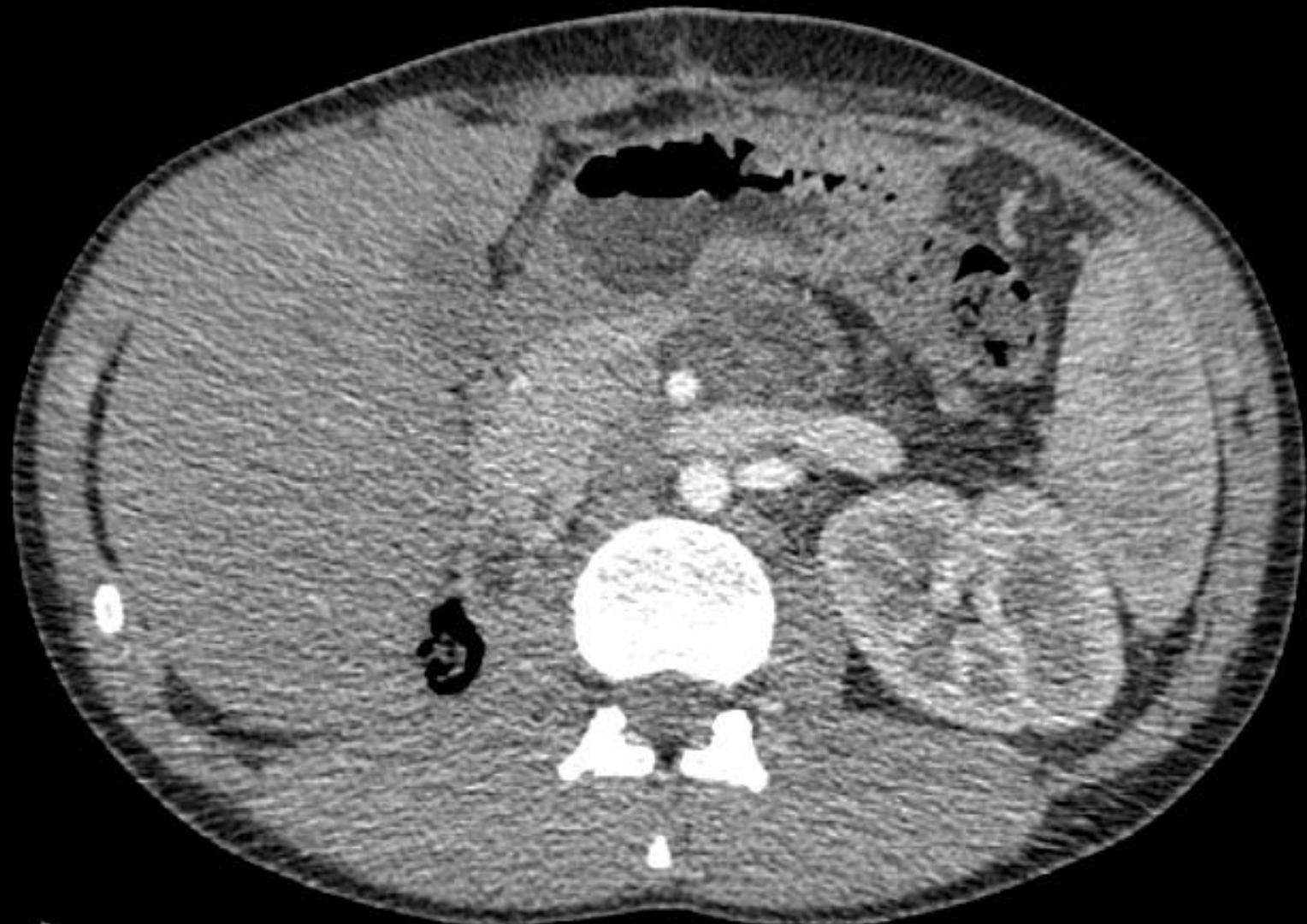Vascular invasion was confirmed, but in the lymphnodes no tumor was detected.






- After the operation the patient has received two other cycles of chemotherapy according to Ewing-VIDE protocol.
- At the moment the patient is well, and according to control CT scans the patient is in total regression.





# Thank you for your attention!



**Eighth European International  
Kidney Cancer Symposium**  
Budapest – 03-04 May 2013

