

Mrs CHL, 45 ans

2 terminations of pregnancy

48 Kg / 1.50m (BMI = 21.33)

eGFR = 76 ml/min

Loss of weight = 8 Kg  CT Scan

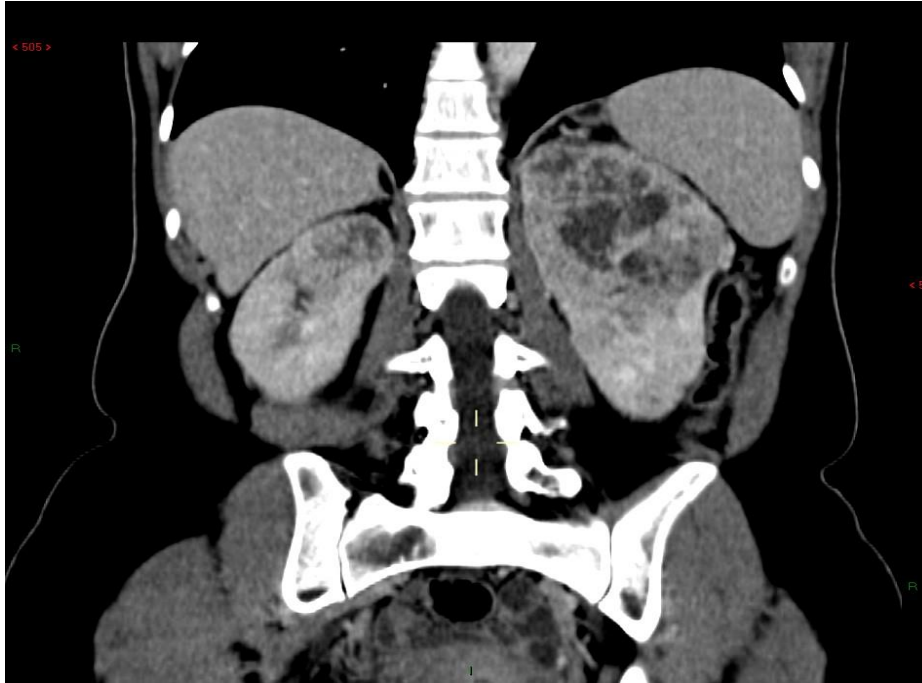


Arnaud Méjean
Professor & Chairman
Department of Urology
Université Paris Descartes
HEGP AHP - Paris

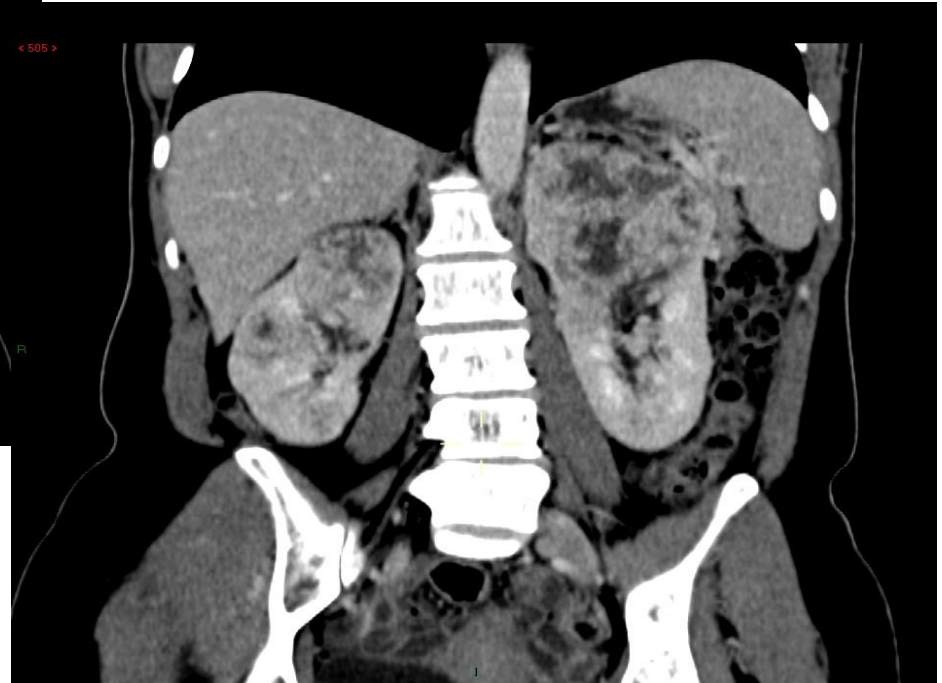


Jan 2011

Left renal tumor = 10 cm



3 right renal tumors



1. Bilateral radical nephrectomy (RN)
2. Bilateral partial nephrectomy (PN)
3. Left RN + Right PN x 3
4. Other option

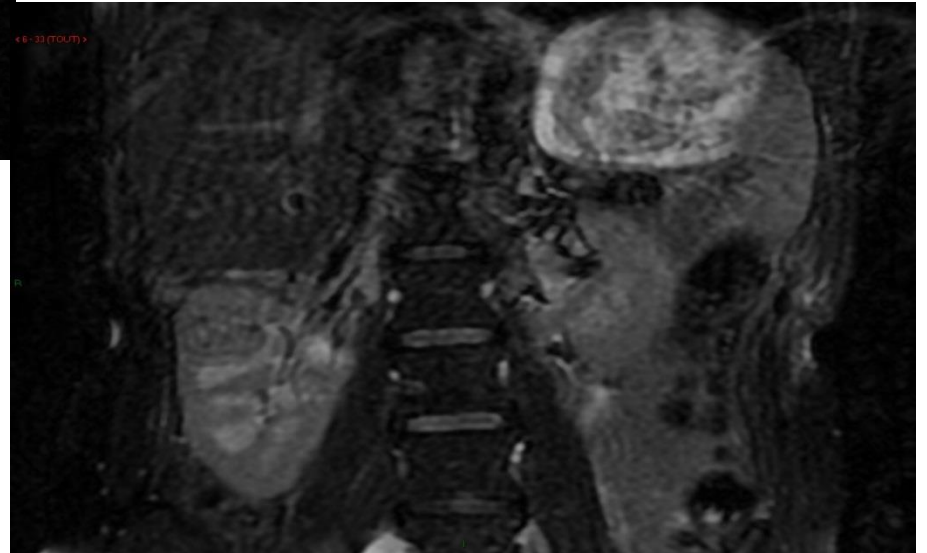
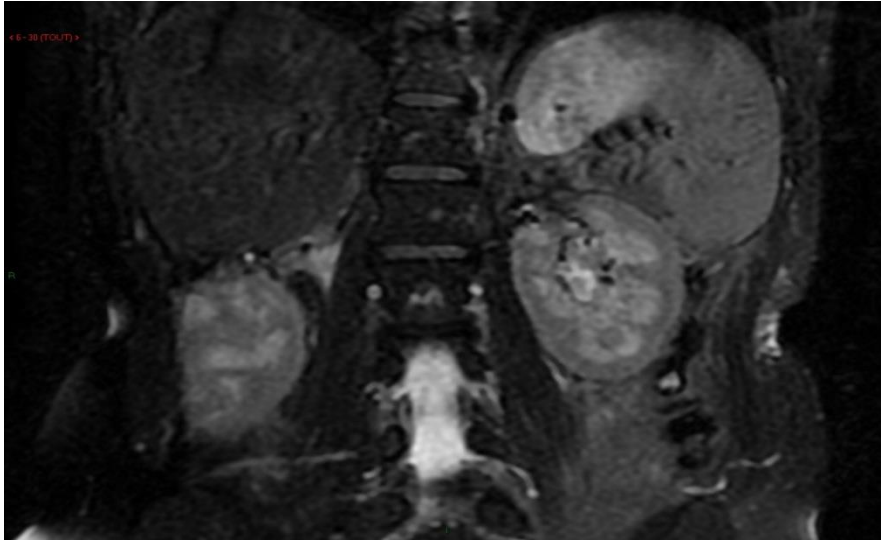
Bilateral PN

- Left : Clear cells RCC 10 cm, Grade 3, 30% necrosis, safe margins
- Right : 3 tumors (4x3x2 cm), similar pathology
- eGFR = 64 ml/min

April 2011

Left : no recurrence

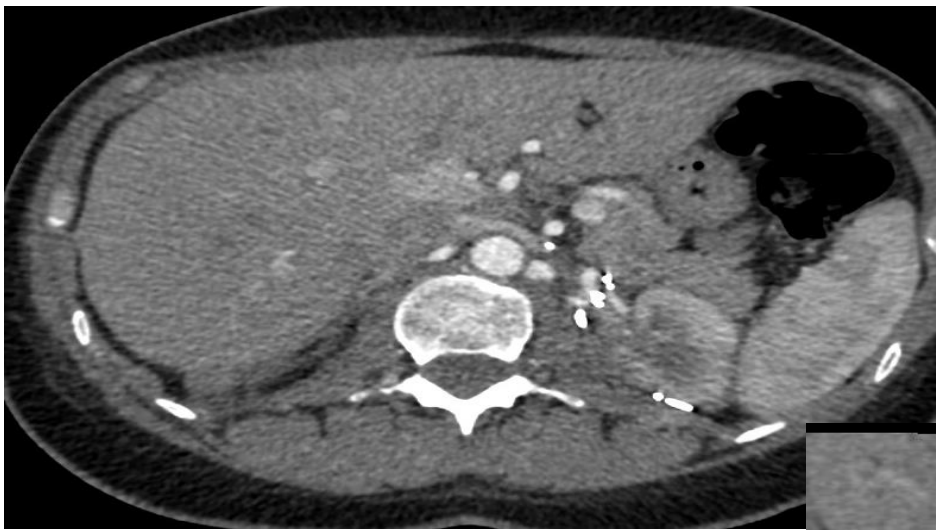
Right : 2 renal tumors
(1x1.2 cm)



1. Right RN ?
2. Right PN ?
3. Ablation ?
4. Other option

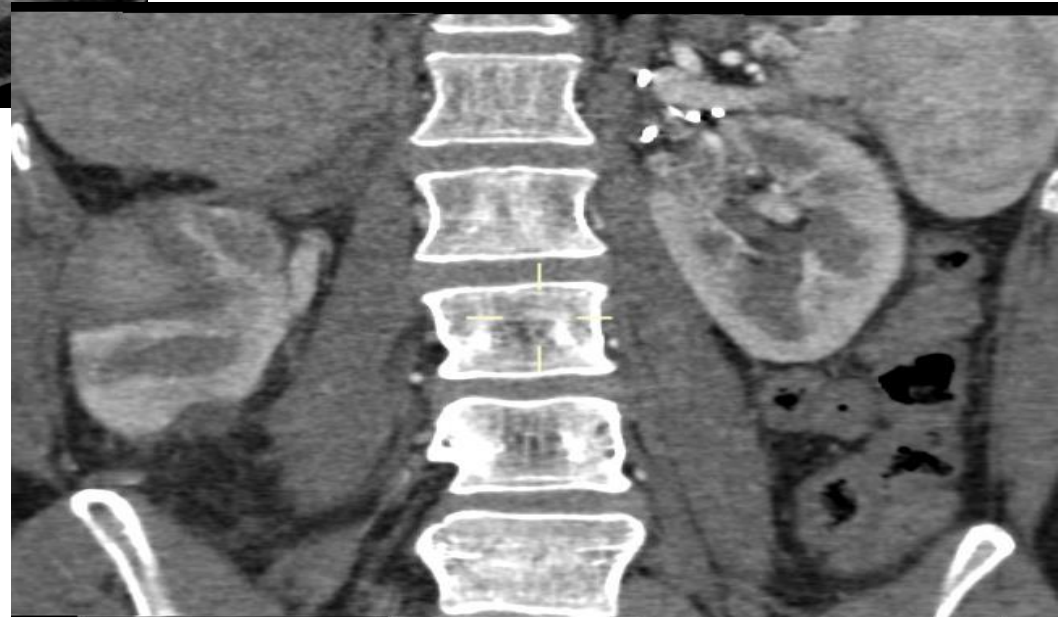RFA

July 2011



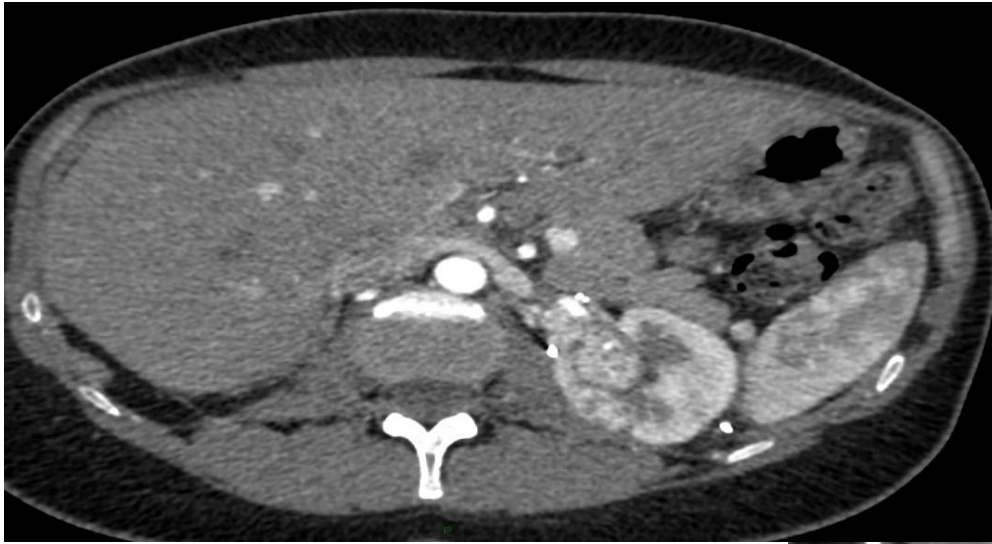
Left : recurrence 1 cm

Right : no recurrence
eGFR = 54 ml/min

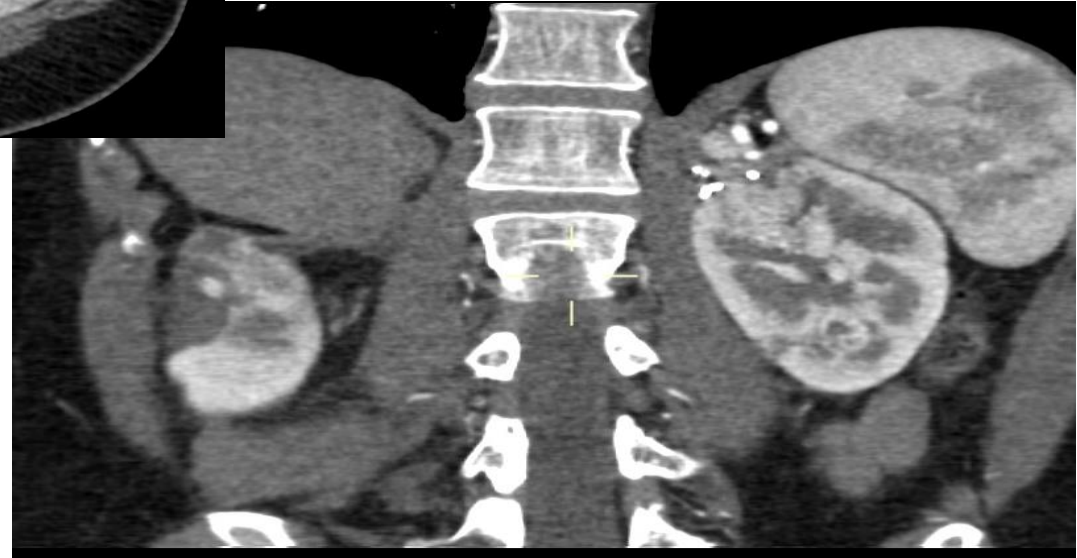

Sept 2011

Left : 3 recurrences



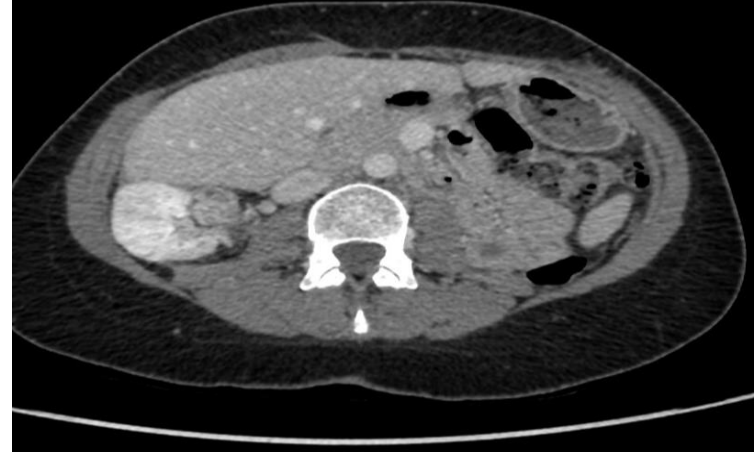
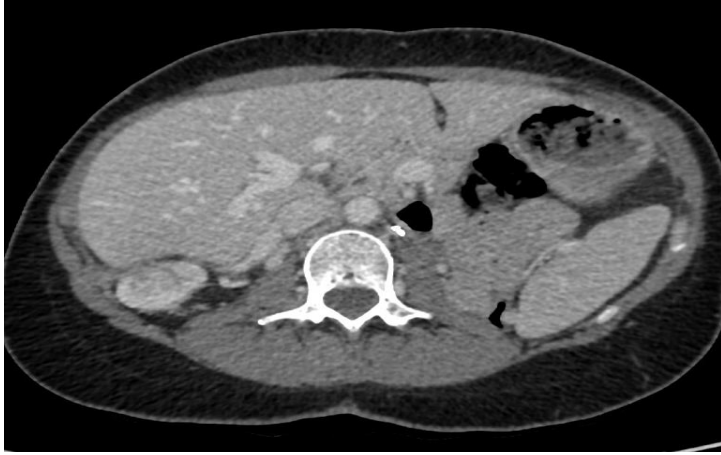Right : no recurrence
eGFR = 58 ml/min



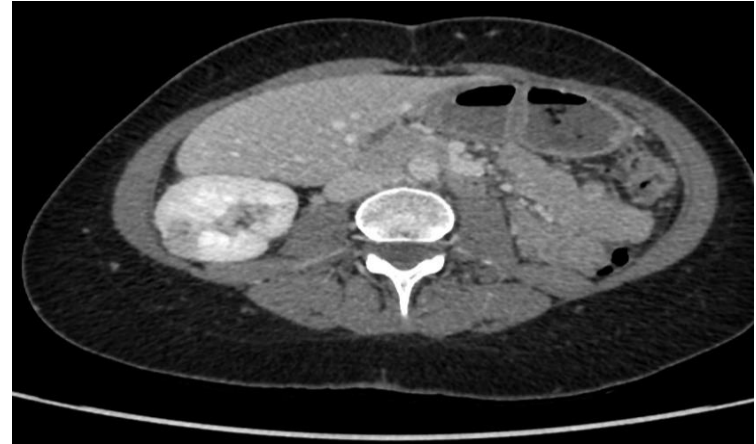1. Left RN ?
2. Left PN ?
3. Ablation ?
4. Other ?

Left RN : clear cells RCC,
3x2x1.8 cm, grade 3

March 2012



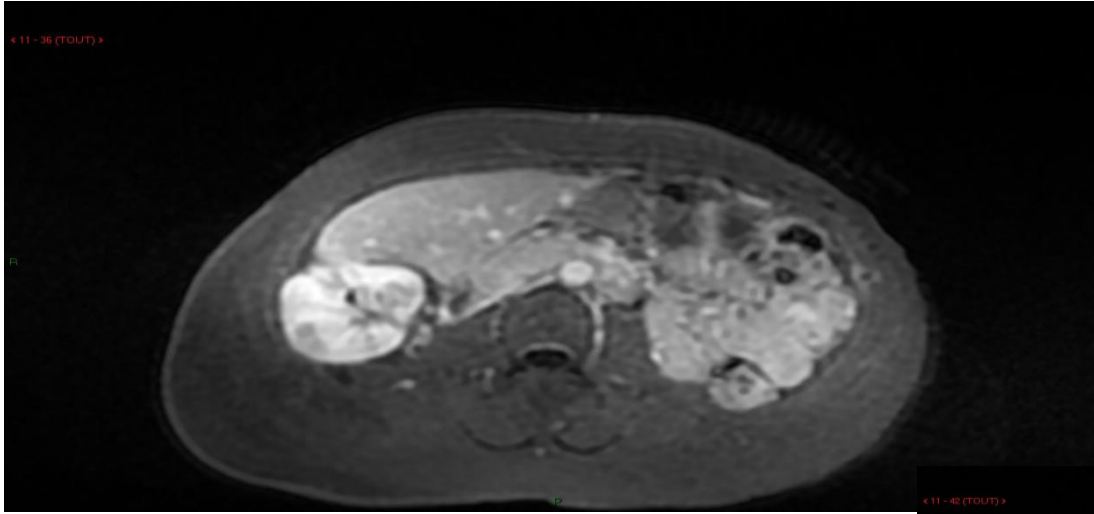
Right : 2 renal tumors
(1.8x1.5 cm)
eGFR = 27.5 ml/min



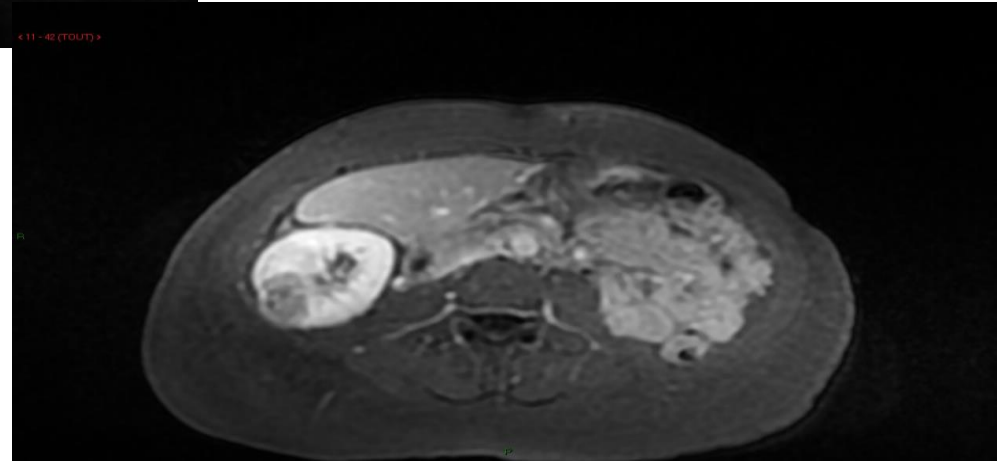
1. Right RN ?
2. Right PN ?
3. New ablation ?
4. Other option ?

Proposition of Right RN +
dialysis but patient refusal

Sept 2012



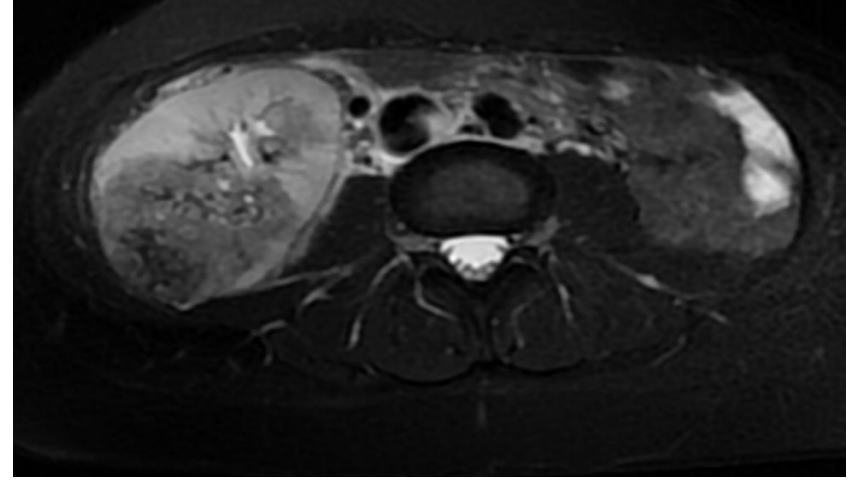
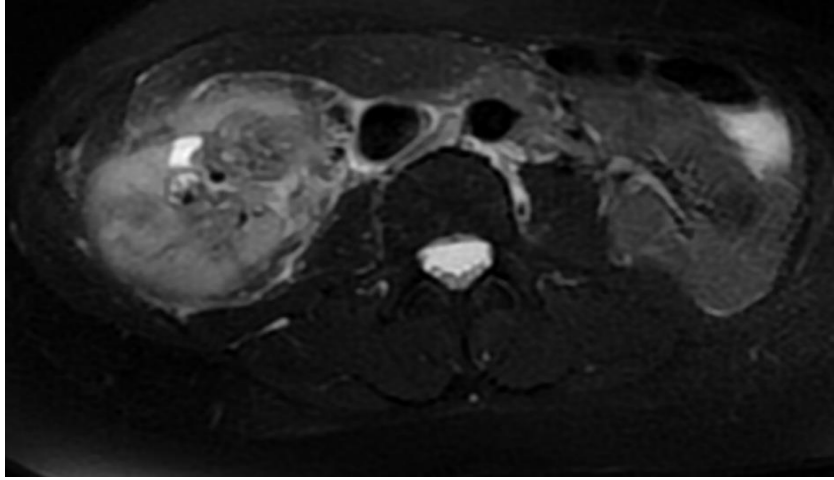
Right : 3 renal tumors
(1.2 x1.8x1.5 cm)
eGFR = 27.5 ml/min



1. Right RN ?
2. Right PN ?
3. New ablation ?
4. Other option ?

Acceptance of right RN

Jan 2013



Right : multifocal tumors +
Vena cava invasion

eGFR = 21.5 ml/min

